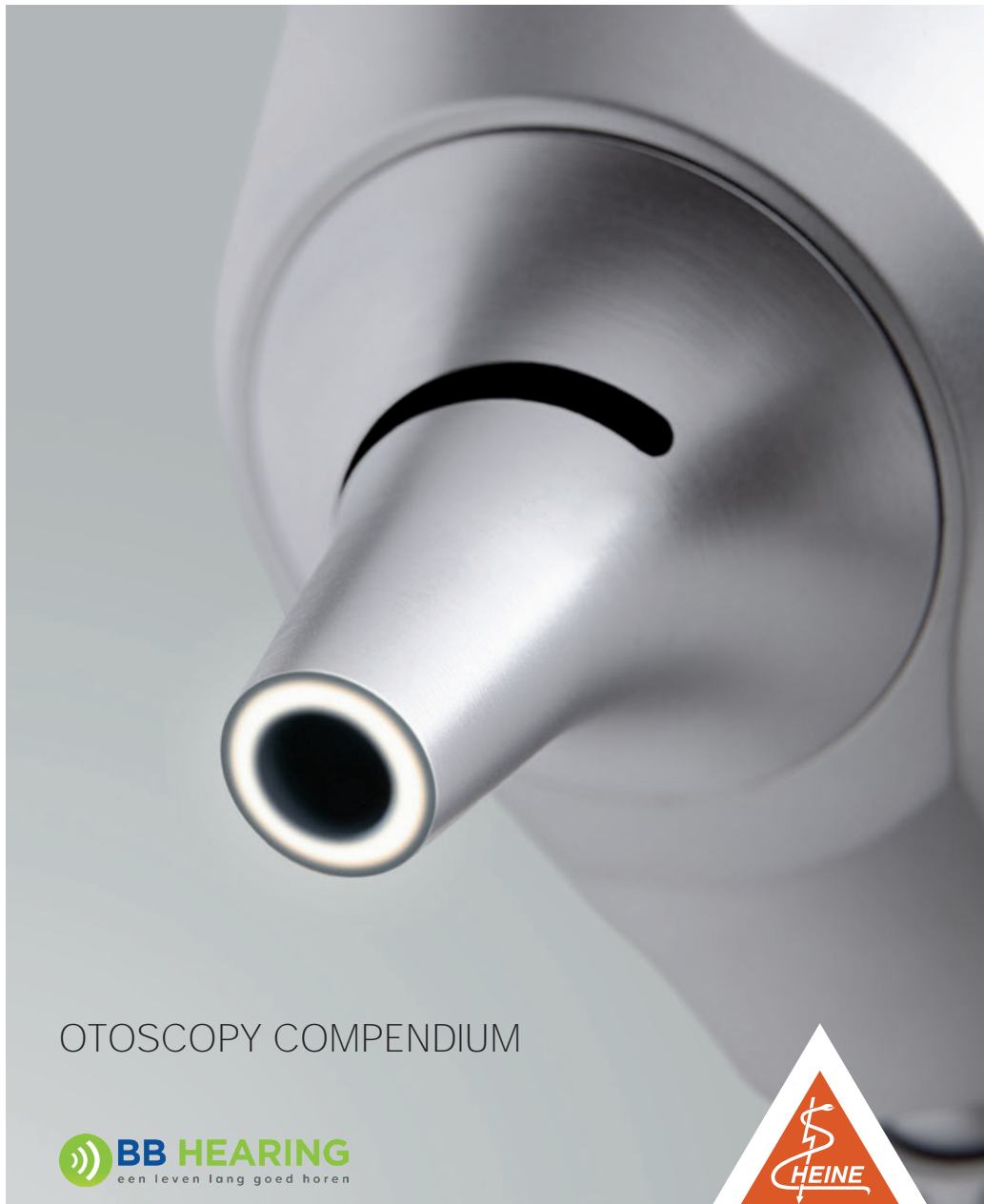


# Practical tips relating to use and assessing findings with extensively illustrated diagnostics atlas.



OTOSCOPY COMPENDIUM





# Contents

1. Otoscopy compendium for beginners .....	05
2. The basic anatomy .....	05
3. Using an otoscope to assess whether or not an eardrum is healthy .....	06
4. The otoscope and its functions .....	07
4.1. Otoscopy.....	07
4.2. The pneumatic test (according to Siegle) .....	08
4.3. Adding instruments .....	09
4.4. Cleaning .....	09
5. Middle ear conditions .....	10
5.1. Acute otitis media.....	10
5.2. Serous otitis media.....	10
5.3. Epitympanic dysventilation syndrome .....	11
5.4. Tympanosclerosis (eardrum sclerosis).....	11
5.5. Barotrauma with serosanguinous effusion (haemotympanum).....	11
6. Eardrum conditions/defects .....	12
6.1. Grommet in situ.....	12
6.2. Chronic perforation of the eardrum .....	12
6.3. Tympanic atelectasis .....	12
6.4. Injury to the ear canal and eardrum after cleaning the ear with cotton buds .....	12
6.5. Acute traumatic perforation.....	13
6.6. Healed central perforation of the eardrum.....	13
6.7. Atypical pigmentation of the eardrum.....	13
7. Outer ear conditions.....	14
7.1. Acute otitis externa.....	14
7.2. Exostosis.....	14
7.3. Foreign bodies .....	14
7.4. Otomycosis .....	15
7.5. Aural polyp .....	15
7.6. Aural haemangioma .....	15
8. HEINE otoscopes .....	16



# 1. Otoscopy compendium for beginners

Otoscopy is one of the routine diagnostic ENT examinations. It is performed by paediatricians, general practitioners, ENT specialists and medically trained staff to assess the outer ear, the ear canal and the eardrum. Vets use otoscopes for diagnostic purposes too.

But assessing the eardrum isn't always easy and requires some clinical experience. A powerful otoscope (also known as an 'auriscope') makes precise diagnostics a breeze thanks to optimum illumination and magnification.

The aim of this otoscopy compendium is to explain how to correctly perform otoscopy procedures in practice and also to assist with assessing findings.

## 2. The basic anatomy

Otoscopy is an examination that allows practitioners to assess the condition of the ear canal and eardrum. The condition of the eardrum allows the examiner to draw conclusions concerning the physiology and function of the middle ear.

The eardrum is a semi-transparent, thin, pearly membrane that is positioned at an angle to the axis of the ear canal. It is covered by a fine layer of skin on the outside and mucous membrane on the inside. The centre of the eardrum (umbo) is pulled inwards (like some people's belly button) by the handle (manubrium) of the hammer that is connected to it.

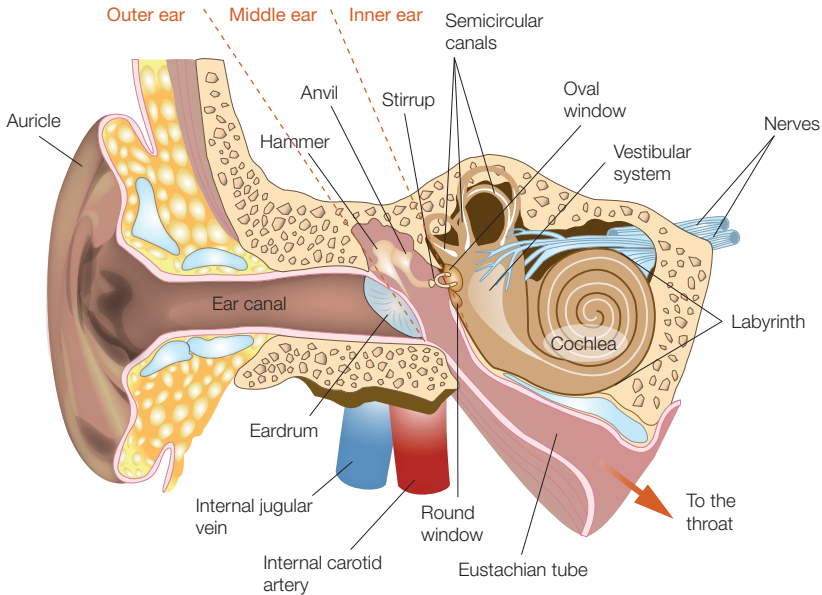
The hammer (malleus) forms part of the auditory ossicles (Ossicula auditus) together with the anvil (incus) and the stirrup (stapes). Both are located in the middle ear cavity (Cavitas tympani). This small, air-filled space in the temporal bone is connected to the air-filled cavities of the mastoid process (Cellulae mastoideae).

The eustachian tube (Tuba auditiva), which ventilates the tympanic cavity, opens out on the tympanic cavity's caudal wall. The upper part is formed of bone, and the following section is made up of cartilage and measures around 4 centimetres long overall. The opening ends in the dorsal nasopharyngeal space.

The eustachian tube equalises pressure in the middle ear with outside air pressure, allowing the eardrum to vibrate normally to transmit sound.

This mechanism in the eustachian tube opens to do exactly that each time you swallow. This also explains why it is the most common route of infection for inflammation of the middle ear (otitis media).

### 3. Using an otoscope to assess whether or not an eardrum is healthy



**A normal result forms the basis of assessing the eardrum. This is characterised as follows:**

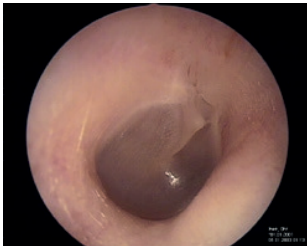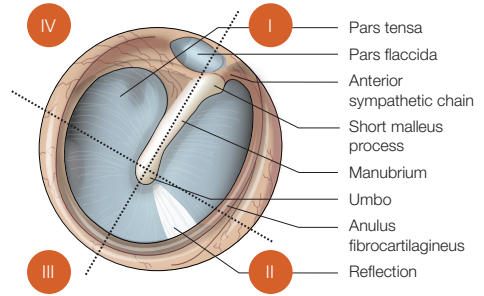
- 1. Colour:** A healthy eardrum is semi-transparent, pearly and not reddened by inflammation.
- 2. Light reflection:** The smooth squamous epithelium layer of the eardrum creates typical light reflections when illuminated by the otoscope. In most cases, a **triangular light reflection is visible in the lower right quadrant**. The normal reflection disappears or can be seen elsewhere if pathological changes have occurred.
- 3. Distinct structure:** The normal anatomical structures such as the Anulus fibrocartilagineus and the manubrium are visible. In contrast, if there is acute inflammation, the eardrum is de-differentiated. In other words, it is not possible to distinguish between the aforementioned structures with any real certainty.
- 4. Mobility: When the eardrum is working, it vibrates with as little restriction as possible.** This mobility can be checked by performing pneumatic otoscopy (according to Siegle), to name but one example, and is usually best detected in the posterior upper quadrant.

### Symptoms:

The surface of the eardrum (which is visible with an otoscope) is split into 4 areas, where the base axis always runs through the manubrium.

- I. Anterior upper quadrant
- II. Anterior lower quadrant
- III. Posterior lower quadrant
- IV. Posterior upper quadrant

This is why you should always look for the structure of the manubrium first as a reference point.



### Normal results

Normal results for the eardrum reveal a pearly grey, shimmering and semi-transparent membrane without any redness. It is funnel-shaped and curves inwards towards the centre of the eardrum (umbo), allowing the manubrium, which is attached to the eardrum, to shine through. In the anterior lower quadrant (at about 120°), a triangular light reflection is visible if the eardrum's curvature is normal.

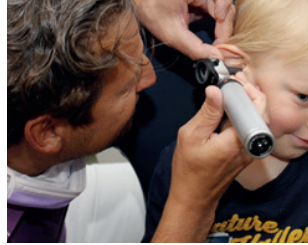## 4. The otoscope and its functions



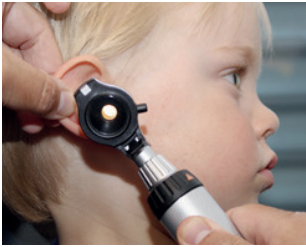[01]

### 4.1 Otoscopy

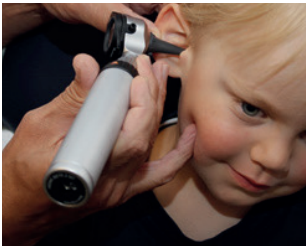1. First of all, carefully examine the auricle and retroauricular skin. Palpate the auricle to identify any tenderness on palpation.
2. Examine the entrance to the ear canal to see if there is any earwax (or other influences) that may interfere with further assessment.
3. Choose the largest ear tip that can still be easily inserted into the ear canal. Put the tip on the otoscope and turn it clockwise to lock it into place. [01]



4. Stretch the external ear canal by pulling the auricle backwards and upwards for adults – or backwards and downwards or horizontally backwards for children.



5. You can hold an otoscope in two different ways:
  - a) like a hammer: The thumb and index finger grip the top end of the handle. Rest the middle and ring finger against the patient's cheek. This prevents the otoscope from touching the ear canal in an uncontrolled manner if the patient makes a sudden movement.
  - b) like a pen between the thumb and index finger, with the other fingers bent and resting against the patient's cheek.



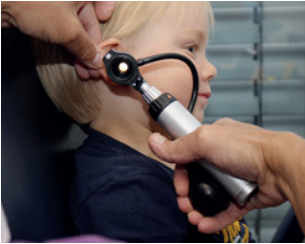6. Do not insert the tip too far (i.e. only insert it into the membranous, outer part of the ear canal) to avoid causing pain and serious injury in the bony inner part of the ear canal.



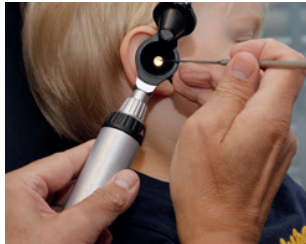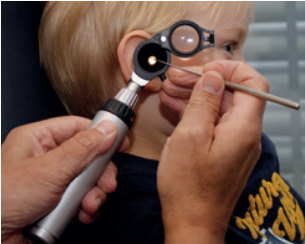#### 4.2. The pneumatic test (according to Siegle)

1. Attach a 'soft tip' to the ear tip to create an airtight space between the eardrum and the head of the otoscope. The head of the otoscope must be inserted in the ear canal such that no air can escape from the side.



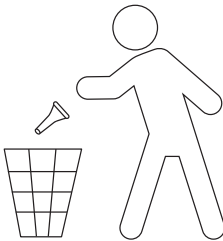

2. Hold the otoscope and the insufflation bulb with one hand at the same time, using the other hand to pull the auricle backwards slightly. After carefully inserting the otoscope, squeeze the insufflation bulb to change the air pressure in the ear canal. This shows whether the eardrum is moving. This allows you to diagnose the likes of tympanic cavity effusions and eardrum perforations.



#### 4.3. Adding instruments

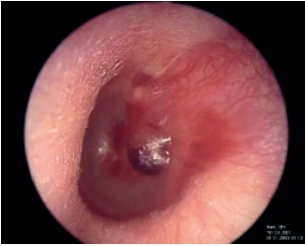To use instruments through the otoscope, the viewing window is pushed to the side or folded upwards. If foreign bodies are lodged deep in the ear canal, and especially when performing examinations on children, any manipulations should only be carried out by an experienced specialist. In some cases, even general anaesthetic may be required.



#### 4.4. Cleaning

Once the examination is complete, single-use tips must be disposed of, because only reusable tips can be safely and hygienically reprocessed and sterilised. The outside of otoscopes can usually be cleaned manually with a damp cloth, while the inside can be cleaned with a cotton bud (wipe cleaning and wipe disinfection). The manufacturer's instructions and corresponding national standards, laws and guidelines apply to hygienic reprocessing of devices and reusable tips.

# 5. Middle ear conditions

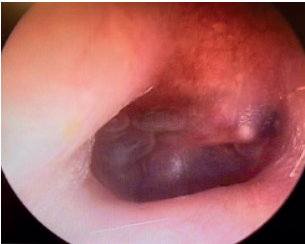


## 5.1. Acute otitis media

**Cause:** Acute infection of the middle ear is a very frequent occurrence, especially in children; mostly as a result of upper respiratory tract infections.

**Symptoms:** severe, stabbing, pulsating earache, often accompanied by fever and cold symptoms. Babies often tug at their ears.

**Results:** In the early stages, the eardrum is retracted and reddened, and the blood vessels are dilated. As the condition gets worse, the eardrum, which is now a fiery red, swells and bulges outwards. This may eventually lead to perforation of the eardrum and leakage of serous or putrid secretions into the ear canal. Under certain circumstances, it may now be impossible to reliably distinguish between the individual structures of the eardrum.

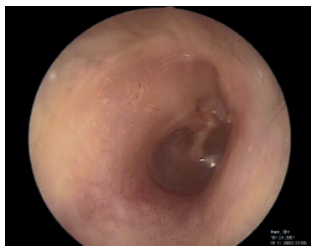

## 5.2. Serous otitis media

**Cause:** It is often caused by swelling of the mucous membrane and obstruction of the eustachian tube, resulting in insufficient ventilation of the tympanic cavity. Air is then reabsorbed in the tympanic cavity, leading to negative pressure in the middle ear, retraction of the eardrum and formation of a serous effusion.

**Symptoms:** Hearing loss, muffled hearing ('water in the ear'), delayed speech development in children, breathing through the mouth.

**Results:** Retraction of the eardrum is visible when looking through the otoscope. The short hammer process jumps forward; the manubrium appears shortened. This leads to the development of a fold in the eardrum. Light reflection has moved away from the umbo. The eardrum may be reddened to varying degrees and may even be the normal colour if the effusion has been present for a long time. If there is an effusion, this shines through the eardrum and reveals fluid bubbles or a fluid level that changes when the head is moved. The eardrum appears less distinct and cloudy.

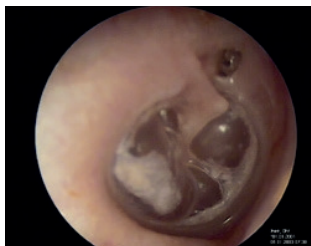

### 5.3 Epitympanic dysventilation syndrome

**Cause:** Chronic negative pressure in the tympanic cavity due to the eustachian tube lacking capacity to equalise pressure.

**Symptoms:** Hearing loss, difficulty with breathing through the nose.

**Results:** Retracted eardrum, light reflection displaced. Pars flaccida retracted.

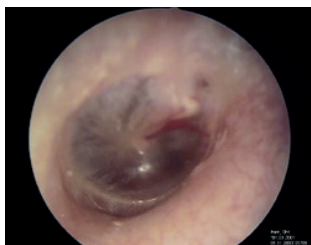

### 5.4 Tympanosclerosis (eardrum sclerosis)

**Cause:** Chronic recurrent otitis media

**Symptoms:** Conductive hearing loss

**Results:** Post-infectious deposits with calcification of thickened collagen fibres in the eardrum's middle layer of connective tissue, with additional atrophic eardrum scarring and epitympanic retraction, which may lead to a cholesteatoma.



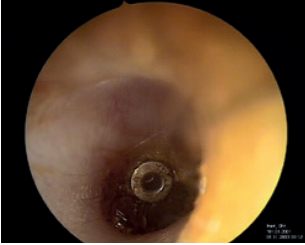
### 5.5 Barotrauma with serosanguinous effusion (haemotympanum)

**Cause:** Rapid, high pressure change if there is insufficient pressure equalisation (e.g. when diving or flying). Formation due to massive negative pressure in the tympanic cavity.

**Symptoms:** Acute, stabbing earache, often with hearing loss and a feeling of pressure on the affected ear.

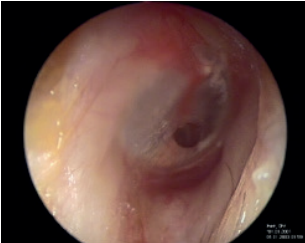**Results:** Oedema of the mucous membrane with vascular rupturing and bleeding into the eardrum, as well as serous tympanic effusion.

## 6. Eardrum conditions / defects



### 6.1 Grommet in situ

Grommets are inserted into the eardrum to ventilate the middle ear in the case of chronic serous otitis media. Otoscopy reveals whether the grommet is freely passable or blocked by debris and secretion. It is also possible to assess whether the grommet is still in the eardrum or has already been expelled and the eardrum has closed again.

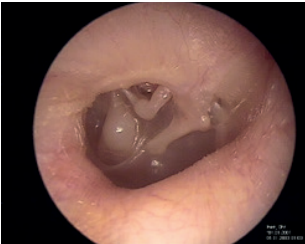

### 6.2 Chronic perforation of the eardrum

**Cause:** If there is pre-existing tympanic scarring following repeated middle ear infections in early childhood or even due to trauma or infections, permanent perforation of the eardrum's pars tensa can occur; sometimes, this does not heal, in which case it should be treated surgically.

**Symptoms:** Hearing loss

**Results:** Round defect in the second quadrant.

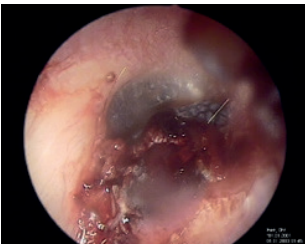

### 6.3 Tympanic atelectasis

**Cause:** Chronic middle ear infections with chronic epitympanic dysventilation syndrome and adhesion of the retracted eardrum to the anvil and stirrup.

**Symptoms:** Hearing loss

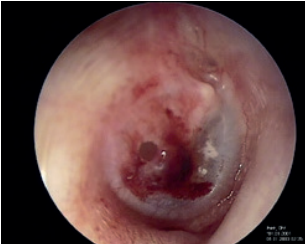**Results:** Ossicles (stirrup and anvil) visible. Altered light reflection; eardrum vibration clearly restricted or even stopped.



### 6.4 Injury to the ear canal and eardrum after cleaning the ear with cotton buds

This resulted in exfoliation of the skin in the ear canal, with erosion of the outer epithelium layer of the eardrum and haemorrhage.

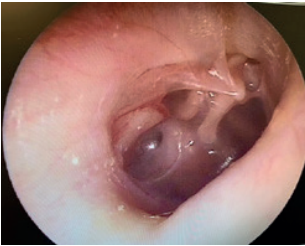
**Results:** Oedema of the mucous membrane with vascular rupturing and haemorrhages into the eardrum and a serous tympanic effusion.



### 6.5 Acute traumatic perforation

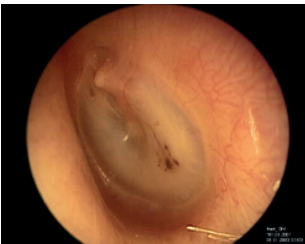**Cause:** Many different causes possible (such as a blow to the ear, a loud bang or penetration of cotton buds or hairpins). Most traumatic perforations heal on their own. But, for this to happen, the ear canal must be kept clean and dry to prevent secondary infection.

**Results:** Different sizes and shapes, but mostly with clear distinction. Sometimes, fresh blood is visible at the edge of the perforation and in the ear canal. The edge of the eardrum is often inverted into the tympanic cavity.



### 6.6 Healed central perforation of the eardrum

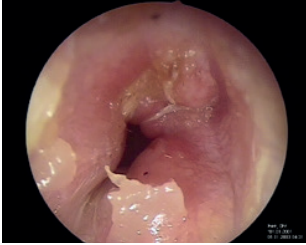When a large perforation heals, the middle layer of the eardrum remains deficient, so a thin, clearly transparent pseudomembrane may look like an open perforation. Performing a careful pneumatic check will prove that the eardrum is intact. The thinned segment of a healed eardrum is not as robust as a normal one, making it susceptible to re-perforation – like during ear irrigation.



### 6.7 Atypical pigmentation of the eardrum

Rare naevus cell naevus.

## 7. Outer ear conditions

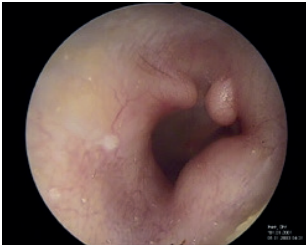

### 7.1 Acute otitis externa

**Cause:** Injuries (caused by the likes of fingernails, hair clips or cotton swabs) and moisture.

**Symptoms:** The skin of the ear canal hurts and is inflamed and swollen. Tugging on the ear and applying pressure to the tragus are typically painful.

**Results:** It may not be possible to see the eardrum because of the swelling, redness and secretion. For local treatment to be effective, the ear canal must be cleansed of secretions and deposits first of all.

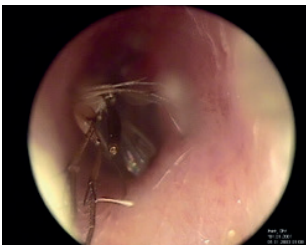

### 7.2 Exostosis ('surfer's ear')

**Cause:** Exostoses are local, spherical bone growths in the ear canal due to irritation of the periosteum (e.g. due to cold water repeatedly penetrating the ear canal).

**Symptoms:** Mostly asymptomatic. Exostoses grow very slowly. Narrowing of the ear canal often leaves unpleasantly noticeable water residue in the ear canal, which can cause inflammation. Hence the name 'surfer's ear'.

**Results:** Spherical narrowing of the ear canal. The otoscope should not be inserted too deeply, as the skin over the exostosis is extremely sensitive to pain.



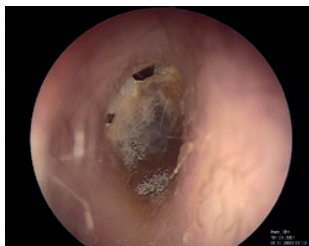### 7.3 Foreign bodies

**Cause:** A wide variety of foreign bodies are often identified in children's ear canals – in this photo, the foreign body is an insect. Cotton wool residues are often discovered in adults' ear canals.

**Symptoms:** The foreign body itself, or failed removal, can lead to secondary painful otitis externa or injure the eardrum and ossicles.

**Results:** Insect with secondary swelling and slight redness of the external ear canal.

**Note:** Removal should only be performed by a specialist. In young children, it is sometimes appropriate to apply a short general anaesthetic to safely remove foreign bodies that are lodged in the ear canal.

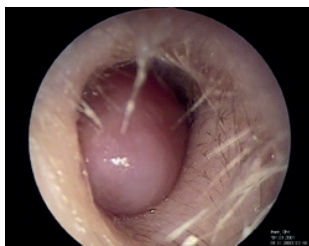

#### 7.4 Otomycosis

**Cause:** Infection with fungi (here: *Aspergillus fumigatus*) – also as a potential consequence of ear drops containing antibiotics or cortisone, or in immunosuppressed patients.

**Symptoms:** Minor to severe pain, mostly on one side; very often extreme itching at first.

**Results:** White/cream-coloured, moist, greasy deposits in the ear canal, which can appear flaky due to the tiny mycelial fibres. If the fungal infection is caused by *Aspergillus niger*, the tiny grey-black spore carriers can also be identified. The skin of the ear canal underneath is usually inflamed and granularly ulcerated due to colonisation with fungal mycelium.

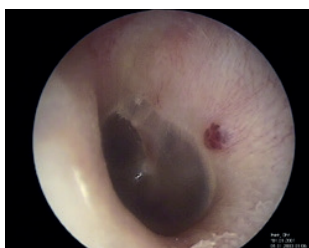

#### 7.5 Aural polyp

**Cause:** Tumour originating from the mucous membrane of the middle ear in the case of eardrum perforation and chronic middle ear inflammation or cholesteatoma.

**Symptoms:** Often associated with foul-smelling secretion from the ear canal and accompanied by marked hearing loss. Chronic ear secretion.

**Results:** Reddish, slightly oozing, oscillating tumour that often fills the entire ear canal and bleeds easily when touched.



#### 7.6 Aural haemangioma

**Cause:** Idiopathic, benign vascular tumour of the skin in the ear canal.

**Symptoms:** Mostly asymptomatic.

**Results:** Reddish, vascularised growth in the external ear canal.

## 8. HEINE OTOSCOPES

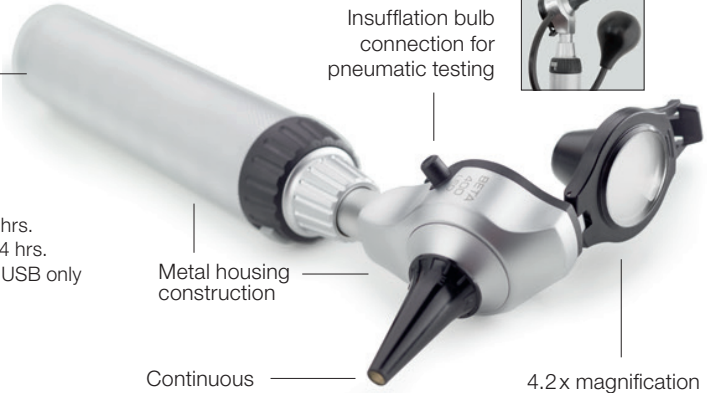
Precision in sharpness, colour rendering and light intensity

BETA4 rechargeable handles with the latest Li-ion technology offer very quick charging times\* and an additional charge status indicator\*\*

\*BETA4 NT (Li-ion) typ. 2 hrs.

BETA4 USB (Li-ion) typ. 4 hrs.

\*\*With BETA4 NT, BETA4 USB only



HEINE NT4  
table charger

**LEDHQ**  
LED IN HEINE QUALITY.

**Efficient charging due to state-of-the-art Li-ion technology.** Lasts twice as long as NiMH batteries, quick charging times (2 hrs. with BETA NT 4), overcharge protection and an additional charge status indicator.

### 5-year manufacturer's guarantee.

The high-quality metal housing construction guarantees a long service life.



### Maximum magnification. Clear-cut. High-resolution.

Quick and precise assessment of anatomical structures due to multi-coated precision optics with 3x to 4.2x magnification.

### Bright and homogeneous exposure. Accurate colour rendering.

The fibre optics (F.O.) allow a shadow-free and glare-free view of the ear canal and eardrum.

HEINE otoscopes have the best product quality. You can find more information about HEINE quality at [www.heine.com](http://www.heine.com). That way, they guarantee general practitioners, paediatricians, ENT specialists, traumatologists, occupational physicians, EMS staff and medical professionals the earliest possible and most accurate diagnosis.



# HEINE OTOSCOPES

The right otoscope for every need



	BETA 400	BETA 200	K180	mini 3000
<b>Viewing window</b>				
Magnification Optics	4.2x	3x	3x	3x
Adding instruments	Precision optics (glass, multi-coated)	Precision optics (glass, multi-coated)	Acrylic	Acrylic
Instrumentieren	Hinged	Swivelling	Swivelling	Swivelling
<b>Illumination</b>				
F.O. or direct	F.O.	F.O.	F.O.	F.O.
LED <sup>HQ</sup>	+	+	-	+
XHL	+	+	+	+
Brightness control	Continuous	Continuous	Continuous	on/off
<b>Ear tips</b>				
HEINE AllSpec disposable tips – new: Now made of recycled plastic or reusable tips (see p.18)				
<b>Housing construction</b>				
Material	Metal	Metal	Polycarbonate	Polycarbonate
Size	Professional	Professional	Professional	Compakt
Insufflation bulb connection	+	+	+	Additional connector required
<b>Available power sources</b>				
With corresponding table charger	+	+	+	+
3.5/2.5V USB rechargeable battery	+ / 0	+ / 0	+	+
2.5V battery	+	+	+	+(AA)

The BETA 400 and 200 lines are particularly suitable for everyday practical use. The high-quality optics with up to 4.2x magnification and the bright light enable precise and quick ear diagnostics for many years to come. The instruments with a polycarbonate housing construction weigh less, making them ideal for when practitioners are on the move or for storage in the smock pocket. The mini 3000 units stand out as faithful companions with bright heads and LED F.O. optics. All instruments are covered by the HEINE quality promise with a 5-year manufacturer's guarantee.

# ACCESSORIES FOR HEINE OTOSCOPES

## HEINE AllSpec disposable tips

Now made of recycled plastic like EcoTips:

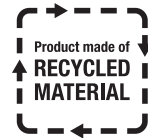- ▶ The **usual HEINE quality** is now saving tonnes of CO<sub>2</sub>.
- ▶ **For a particularly secure fit, outstanding light transmission and hygiene.**
- ▶ **Assured quality.** No sharp edges.
- ▶ AllSpec disposable tips are available in the sizes Ø 2.5 mm and Ø 4 mm and come in packs of 250 [01] or 1,000 units [02].



[01]



[02]



## Reusable tips

- ▶ **Tips made of shockproof SANALON S plastic with smooth surfaces.**  
Easy to clean. Disinfection with common agents and sterilisation in a steam autoclave up to 134 °C.
- ▶ The reusable tips can be used several times and are easy to reprocess.  
Available in the following sizes: Ø 2.4mm, Ø 3mm, Ø 4mm and Ø 5mm.



## AllSpec tip dispenser

- ▶ The correct size is clearly visible and easy to remove with the AllSpec tip dispenser.



**Disclaimer:** This otoscopy compendium and the information and practical advice it contains concerning the appropriate use of otoscopes are based on the proper evaluation of relevant publications and legal requirements. Under no circumstances is the information a substitute for professional advice or treatment by a trained and accredited practitioner. Patients or other third parties may under no circumstances make independent diagnoses or start treatment. Instructions for use must be followed as a matter of priority. Diagnosis is the sole responsibility of the attending practitioner.

**HEINE Optotechnik GmbH & Co. KG**  
Dornierstr. 6, 82205 Gilching, Germany  
E-Mail: [info@heine.com](mailto:info@heine.com), [www.heine.com](http://www.heine.com)

© 2022 by Dr. Königsberger and HEINE Optotechnik GmbH & Co. KG.  
All rights reserved.

